

STUDY THE EFFECTS OF ANADROL OVERDOSE ON KIDNEY IN RAT MODEL

Ali Hadi MOHAMMED

Al-Qasim Green University, Iraq

Ahmed Obaid HOSSAIN¹

Al-Qasim Green University, Iraq

Abstract

Background: Anadrol is an active androgenic anabolic steroid that has been clinically studied in numerous diseases since the 1960s. It is used in the treatment of anemia and the replacement of male sex steroids. Unfortunately, in attempts to improve physical performance, Anadrol could be misused by athletes, that can lead to poisoning contributes to renal toxicity.

The Aim: This study aims to investigate nephrotoxicity of anadrol via assessment of renal injury markers and histopathological study.

Materials and methods: A forty male rats, weights about (200-300 gm), aged 8-12 weeks, after acclimatization, the rats were randomly divided into four groups (n=10) : control group (in which all rats were administered normal saline (NS) via oral gavage), anadrol 10 mg/kg group (in which all rats were administered anadrol 10mg/kg via oral gavage), anadrol 20 mg/kg group (in which all rats were administered anadrol 20mg/kg via oral gavage), and anadrol 30 mg/kg group (in which all rats were administered anadrol 30mg/kg via oral gavage), the oral administration had continued for 8 weeks. At the end of study urea & creatinine were measured via chemical analysis. Then renal histopathological study was done.

Results: Rats treated with anadrol displayed high level of urea & creatinine, as compared with control group. On the other hand, histopathological study exhibited significant injurious changes in the renal tissue in anadrol groups comparing with control.

Conclusion: When given in high doses anadrol results in renal injury, that can be cleared via both elevated levels of renal injury markers and renal histopathological changes.

Keywords: Anadrol, Renal injury, Urea, Creatinine, Anabolic Androgenic Steroid.



<http://dx.doi.org/10.47832/2717-8234.11.28>



¹ ahmed.e@biotech.uoqasim.edu.iq

Introduction

Anadrol as anabolic androgenic steroid that had been clinically studied in numerous diseases since the 1960s. It is used in the treatment of anemia and the replacement of male sex steroids as a stimulator of bone marrow cells also it is used in some illnesses to improve general weakness. Unfortunately, in attempts to improve physical performance, Anadrol could be misused by athletes and is therefore classified as 'controlled substance schedule III.' Anadrol poisoning contributes to renal toxicity, prostatic hypertrophy, azoospermia, and impotency ¹.

As a testosterone 17- α derivative, Anadrol demonstrate its anabolic effects via one of two mechanisms, either by direct activation of androgen receptors or indirectly by activation of specific estrogen receptors after its conversion to estradiol. The next step is that transportation of free testosterone into the cytosol of target cells and tissues, then either make binding with androgen receptors or undergo reduction, through the activity of 5 α -reductase (cytoplasmic enzyme), into 5 α -dihydrotestosterone (DHT). The latter mediator, 5 α -dihydrotestosterone (DHT), will make stronger binding with androgen receptor (2.5 times) as compared with testosterone. After binding the drug-receptor complex will undergo conformational and structural changes, that result in entry of the drug molecules into the nucleus, followed by direct binding with hormone response elements (HREs), which include specific sequences of DNA nucleotides, then lead to gene expression and finally end with the required androgenic effects ².

Anadrol, which had been approved as anabolic steroid by Food and Drug Administration (FDA), considered the potent one in body building as comparing to other anabolic steroids, in such condition body builder can get about 14.5 pounds/100 pounds of their weight ³. Furthermore, it is also cheaper, have higher activity, but mandatory monitoring of renal function should be done routinely ^{3, 4}. Anabolic-androgenic steroid (AAS) overdoses usually accompanied with central nervous systems related abnormalities including cognitive abnormalities and Al Alzheimer's symptoms ⁵. Long-term supraphysiologic-dose AAS exposures are associated with abnormalities in liver and kidney ⁶.

Dietary supplements and anabolic steroids, that used by athletes to modulate lean body mass and increase the muscle strength, can adversely affect their functioning organ, among organ that affected is the kidney, which consider the important site for biotransformation and excretion of such substances ^{7, 8}. Many drugs, both legal and illegal, can damage the kidneys in different ways. The kidneys' susceptibility to such insults is mainly due to their high degree of filtration and their metabolism of potentially toxic by-products by the kidneys ^{9, 10}. These drugs including anabolic steroids can deteriorate kidney in deferent pathways, they can result in glomerular injury, acute and even chronic kidney injury ¹¹. These injuries have more complicated pathogenesis, which may include renin-angiotensin-aldosterone system (RAAS) stimulation, elevate endothelin production, oxidative stress insult via free radical production, increased expression of pro-apoptotic and pro-fibrotic mediators, in addition to pro-inflammatory cytokines and chemokines ¹².

Rhabdomyolysis is a severe condition that results from skeletal muscle injury and the subsequent release of breakdown products from injured muscle cells into the bloodstream. Strenuous activity, muscular hypoxia, medicines, and drug misuse are the most common causes of muscle damage, which can result in serious consequences including acute renal injury (AKI). Rhabdomyolysis due to drug use and the consequent acute kidney injury are among the lethal risks associated with anabolic steroid abuse. In most cases, the symptoms are extensive and often misleading ^{13, 14}.

However, the renal injury that occur consequently to the abuse of anabolic steroids, including Anadrol, can be documented by the serum increment of renal function parameters such as urea and creatinine ^{12, 15}.

Materials and methods

Animal grouping

Forty adult male rats weighted about (200-300 gm), aged 8-12 weeks, were brought from the consultant bureau, college of science, university of Babylon. Animals were harbored in the animal house with a temperature controlled 20-25°C and 60-65% humidity with a fitted 12 hrs. light and 12 hrs. dark cycle for 14 days before the start of the experiment. Also, the rats were free to access food and water. In this study, the rats were divided randomly into 4 equal groups, 10 rats in each group, and like the following:

1. **Control group:** Rats in this group administered equivalent volume of normal saline (NS) via oral gavage route daily for 8 weeks ¹⁶.
2. **Anadrol 10mg group:** Rats in this group administered anadrol in a dose of 10 mg/kg via oral gavage route daily for 8 weeks ^{17, 18}.
3. **Anadrol 20mg group:** Rats in this group administered anadrol in a dose of 20 mg/kg via oral gavage route daily for 8 weeks.
4. **Anadrol 30mg group:** Rats in this group administered anadrol in a dose of 30 mg/kg via oral gavage route daily for 8 weeks ¹⁹.

At the end of study animals were sacrificed via anesthesia, then blood and renal tissue samples collection had been done as below.

Preparation of drug

Anadrol 50 mg tablet (Iran-Tehran Company) was obtained and dissolved in normal saline as a vehicle to get Anadrol solution, then given via oral gavage according to animal's body weight ¹⁶.

Sample collection

At the end of study, animals were anesthetized with ketamine (50mg/kg) and xylazine (10 mg/kg) [5]. Then blood sampling was done via direct cardiac puncture, furthermore, animals were sacrificed and renal tissues were obtained.

Blood Sampling

Withdrawn blood was let to clot in gel tube then centrifuged at 4000 × g for 10 min to get serum. Then chemical analysis was done on serum samples.

Tissue sampling

After animal scarification with anesthesia renal tissues were obtained and preserved in 10% formalin until histopathological study was done.

Renal function analysis

To get renal function parameters that include serum urea and creatinine, chemical analysis was done measured with a fully automatic biochemical analyser (FUJI DRI-CHEM NX500). Briefly A FUJI DRI-CHEM SLIDE TP-PIII is used to deposit μ L 10 of serum. The specimen spreads uniformly over the special spreading layer after depositing and interacts with the reactive reagent released from the reagent layer to generate color. The optical

reflection density is measured at 540 nm after the slide has been incubated at 37 °C for a set duration in the FUJI DRI-CHEM ANALYZER. Using a calibration curve preloaded in the analyzer, the optical reflection density is translated into total protein concentration ²⁰.

Histopathological analysis

Histological specimens from the renal tissue were prepared at the cancer Research Unit, faculty of Medicine, university of Kufa. Renal tissue samples were fixed in 10% buffered formalin for at least 24 h before processing, as described previously ²¹.

The preserved tissues were first embedded in paraffin wax, then dehydrated using a series of increasing concentrations of ethanol to eliminate any free or bound water. A microtome was used to slice the implanted tissues into a 5 µm piece. Renal slices were mounted on simple glass slides and stained with hematoxylin and eosin (HE) staining for histological evaluation. H & E stained sections were examined under a light microscope for any abnormalities at 100×, 200×, and 400×.

Renal histopathology scoring

The degree of kidney injury was scored based on the grading system done by the previous study²². Briefly, the extent of tissue damages was graded from 0 to 4 depending on the microscopical findings, that included the presence of cellular swelling, increased cytoplasmic eosinophilia, loss of brush borders, and extravasation of RBCs which present in all cases in variable percentage. In addition to the presence of eosinophilic cast in some cases. as shown via table 1.

Table 1: Renal injury scoring system

Score	Description
0	Normal - no change in the tubules
1	Mild - < 25% of tubular injury
2	Moderate - 25% to 50% of tubular involvement
3	Severe - 50% to 75% of tubules showing characteristic change
4	Very severe - more than 75% of tubular damage

Statistical analysis

Statistical analysis was performed using SPSS 26 (SPSS, Inc., Chicago, IL, USA). Analysis of variance (ANOVA) with LSD post-hoc test was used to investigate differences between groups. While histological differences were confirmed using Kruskal-Wallis with Mann-Whitney U-test. Statistically, the present data significance was defined as $p \leq 0.05$.

Results

The effect of Anadrol on renal function

To investigate the effects of Anadrol on renal function, renal injury parameters including serum urea and serum creatinine were carried out in experimental groups via chemical analysis.

The effect of Anadrol on urea

Anadrol 10 mg, 20 mg, and 30 mg groups demonstrated a significant ($p < 0.05$) higher levels of urea as compared with control group. Furthermore, Anadrol 20mg, 30mg groups showed a significant ($p < 0.05$) higher levels of urea as compared with anadrol 10mg group. On the other hand, study showed there is no significant elevated in urea level in Anadrol 30mg group when compared with Anadrol 20mg. These findings were showed in figure 1:

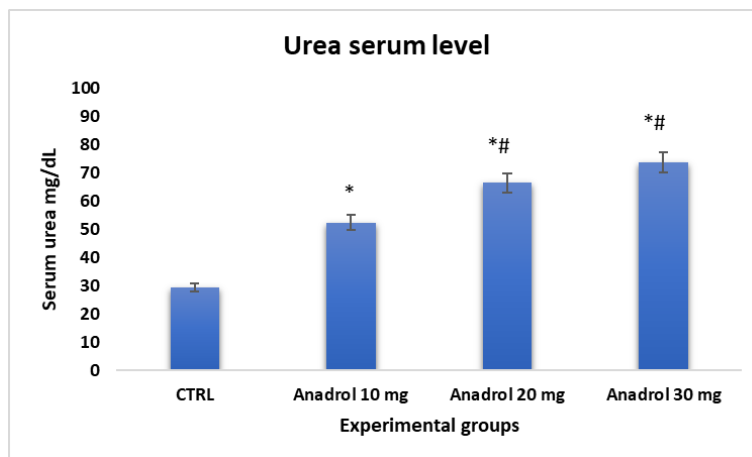


Figure 1: The mean serum ALT level (U/L) in experimental groups: Data are expressed as mean \pm SD; *P <0.05 versus corresponding control; # P <0.05 versus Anadrol 10 mg.

The effect of Anadrol on creatinine

Anadrol 10 mg, 20 mg, and 30 mg groups showed a significant ($p < 0.05$) higher levels of creatinine as compared with control group. Additionally, Anadrol 20 mg, 30 mg groups exhibited a significant ($p < 0.05$) higher levels of creatinine when compared with anadrol 10mg group. Also, current study showed there is no significant elevated in creatinine level in Anadrol 30mg group when compared with Anadrol 20 mg group. These results were summarized in figure 2:

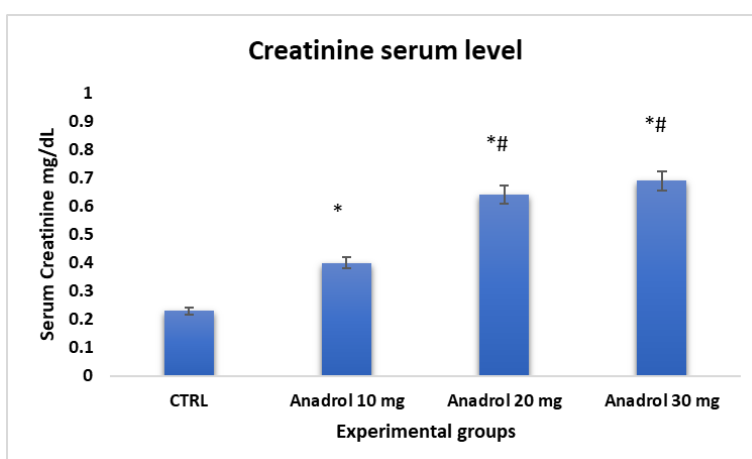


Figure 2: The mean serum creatinine level (mg/dL) in experimental groups: Data are expressed as mean \pm SD; *P <0.05 versus corresponding control; # P <0.05 versus Anadrol 10 mg.

The histopathological effects of anadrol on renal tissue

According to used scoring system the histopathological results of renal tissue of rats of the four experimental groups are summarized by the following table 2 and figure 3.

Table 2: Renal histopathological damage percentage and score of the four experimental groups.

Renal histopathological score	Groups	Damage %	Score
	CTRL	0%	0
	Anadrol 10 mg	36%	2
	Anadrol 20 mg	50%	3
	Anadrol 30 mg	73%	4

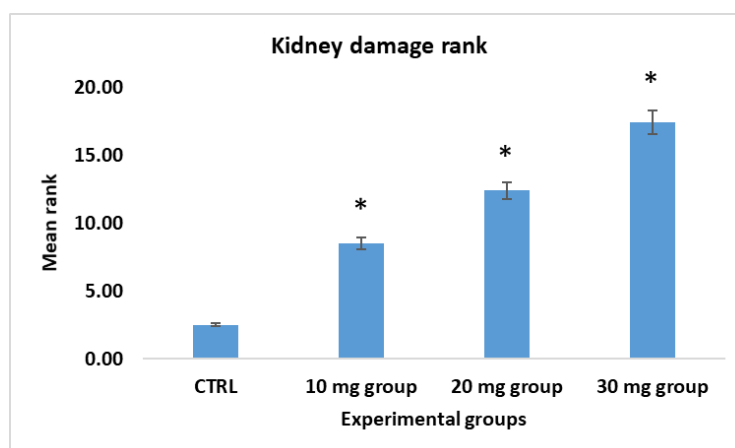


Figure 3: Mean rank of renal damage in experimental groups

Control group

Renal tissue in control group had normal architecture without changes in renal tubules, rats in this group show normal histopathological findings 100%.

According to the used scoring system, the severity of injury showed a zero degree of damaging (score mean = 0 and represent 0% of damage) all rats in this group show normal histopathological findings 100% as shown in figure 4:

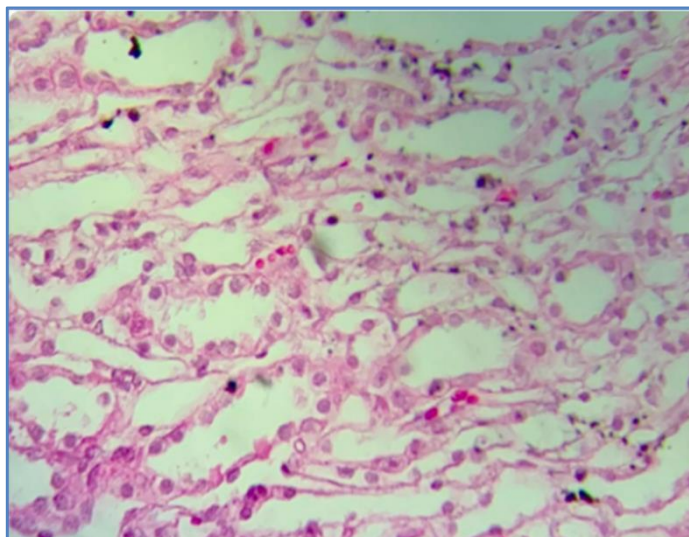


Figure 4: Photomicrograph of rat kidney section of control group shows kidney normal histology, H&E stain 40X10.

Anadrol 10 mg group

Anadrol 10 mg group renal tissue had mild tubular changes in renal tissue. In the term of histopathological grading from normal renal tissue, rats in this group showed tubular injury up to 25% of renal tubules. as shown in figure 5.

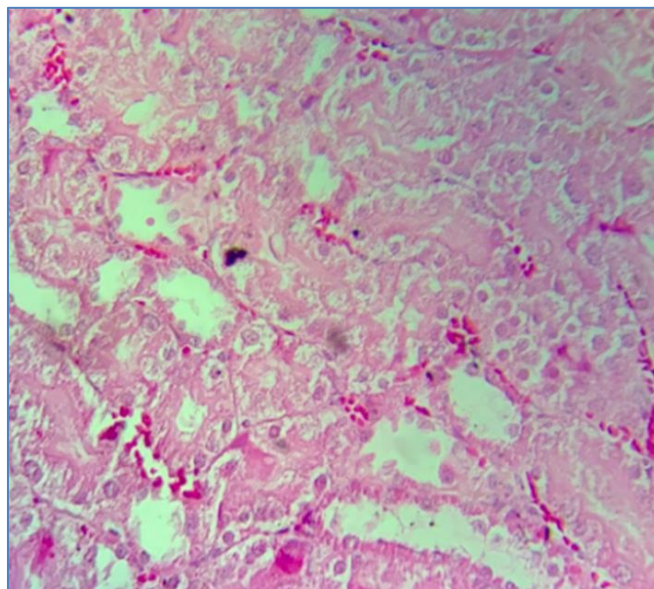


Figure 5: Photomicrograph of rat kidney section of anadrol 10mg/kg group shows renal tubular damage with eosinophilic, H&E stain 40X10.

Anadrol 20 mg group

Anadrol 20 mg group had moderate tubular injury in renal tissue. In the term of histopathological grading from normal renal tissue, rats in this group showed tubular injury up to 60% of renal tubules. as shown in figure 6.

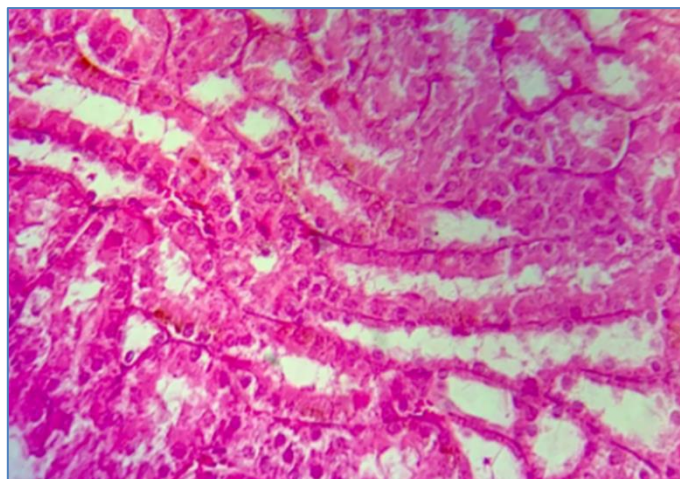


Figure 6: Photomicrograph of rat kidney section of anadrol 20mg / kg group shows moderate renal tubular damage with cellular swelling and increased cytoplasmic eosinophilia, H&E stain 40X10.

Anadrol 30 mg group

Anadrol 30 mg group had severe tubular injury in renal tissue. In the term of histopathological grading from normal renal tissue, rats in this group showed tubular injury up to 90% of renal tubules. as shown in figure 7.

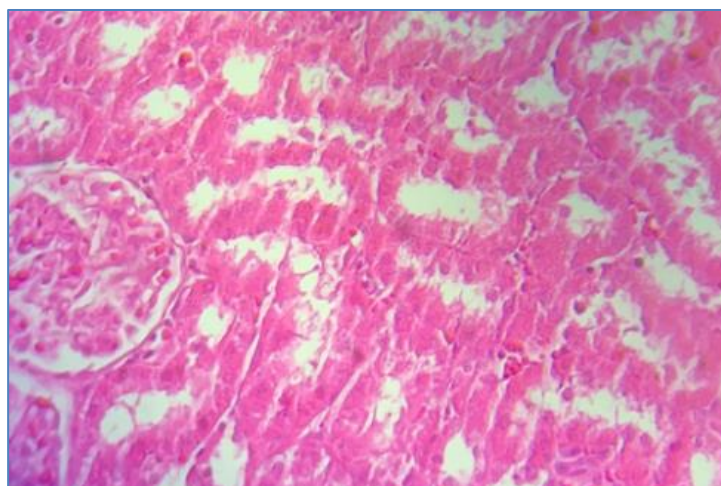


Figure 7: Photomicrograph of rat kidney section of anadrol 30mg / kg group shows severe renal tubular damage, cellular swelling, with marked cytoplasmic eosinophilia, H&E stain 40X10

Discussion

Present study showed significant changes in kidney function among the four experimental groups, that included its effects on the kidney tissue and renal injury markers such as urea & creatinine.

Current study demonstrated a significant increase in the serum level of urea and creatinine in the three anadrol pretreated groups compared with control group. These findings are agreed with previous studies ^{11, 13}. The kidneys' susceptibility to such insults is mainly due to their high degree of filtration and their metabolism of potentially toxic by-products by the kidneys ^{9, 10}.

More interestingly the present study, depending on the microscopic examination of the kidney of rats from four experimental groups and demonstrated that the three anadrol pretreated groups significantly had renal tissue injury including moderate to severe renal tubular damage with cellular swelling and increased cytoplasmic eosinophilia. These outcomes were consistent with previous studies ^{11, 14}. On the other hand, these injuries have more complicated pathogenesis, which may include renin-angiotensin-aldosterone system (RAAS) stimulation, elevate endothelin production, oxidative stress insult via free radical production, increased expression of pro-apoptotic and pro-fibrotic mediators, in addition to pro-inflammatory cytokines and chemokines ^{12,23}

Conclusion

This work found that high doses of anadrol lead to renal injury. Furthermore, it was found that this organ injury confirmed by the elevated level of renal specific injury markers, including urea and creatinine, in addition to the histopathological changes that revealed the renal tissue injury.

References

1. Abdollahi M and Pakzad M. Oxymetholone. In: Wexler P (ed) *Encyclopedia of Toxicology (Third Edition)*. Oxford: Academic Press, 2014, pp.744-746.
2. Pavlatos AM, Fultz O, Monberg MJ, et al. Review of oxymetholone: a 17alpha-alkylated anabolic-androgenic steroid. *Clinical therapeutics* 2001; 23: 789-801; discussion 771. 2001/07/07. DOI: 10.1016/s0149-2918(01)80070-9.
3. Vazquez E. Comparing Oxandrin and Anadrol-50. *Positively aware: the monthly journal of the Test Positive Aware Network* 1998; 9: 49-51. 2001/05/22.
4. Calado RT and Clé DV. Treatment of inherited bone marrow failure syndromes beyond transplantation. *Hematology Am Soc Hematol Educ Program* 2017; 2017: 96-101. DOI: 10.1182/asheducation-2017.1.96.
5. Kaufman MJ, Kanayama G, Hudson JI, et al. Supraphysiologic-dose anabolic-androgenic steroid use: A risk factor for dementia? *Neuroscience and biobehavioral reviews* 2019; 100: 180-207. 2019/03/01. DOI: 10.1016/j.neubiorev.2019.02.014.
6. Modlinski R and Fields KB. The effect of anabolic steroids on the gastrointestinal system, kidneys, and adrenal glands. *Current sports medicine reports* 2006; 5: 104-109. 2006/03/15. DOI: 10.1097/01.csmr.0000306529.74500.f6.
7. Davani-Davari D, Karimzadeh I and Khalili H. The potential effects of anabolic-androgenic steroids and growth hormone as commonly used sport supplements on the kidney: a systematic review. *BMC nephrology* 2019; 20: 198-198. DOI: 10.1186/s12882-019-1384-0.
8. De Francesco Daher E, Mesquita Martiniano LV, Lopes Lima LL, et al. Acute kidney injury due to excessive and prolonged intramuscular injection of veterinary supplements containing vitamins A, D and E: A series of 16 cases. *Nefrologia : publicacion oficial de la Sociedad Espanola Nefrologia* 2017; 37: 61-67. 2016/09/01. DOI: 10.1016/j.nefro.2016.05.017.
9. Perazella MA. Renal vulnerability to drug toxicity. *Clinical journal of the American Society of Nephrology : CJASN* 2009; 4: 1275-1283. 2009/06/13. DOI: 10.2215/cjn.02050309.
10. Loghman-Adham M, Kiu Weber CI, Ciorciaro C, et al. Detection and management of nephrotoxicity during drug development. *Expert opinion on drug safety* 2012; 11: 581-596. 2012/05/24. DOI: 10.1517/14740338.2012.691964.
11. Parente Filho SLA, Gomes P, Forte GA, et al. Kidney disease associated with androgenic-anabolic steroids and vitamin supplements abuse: Be aware! *Nefrologia : publicacion oficial de la Sociedad Espanola Nefrologia* 2020; 40: 26-31. 2019/10/06. DOI: 10.1016/j.nefro.2019.06.003.
12. Davani-Davari D, Karimzadeh I and Khalili H. The potential effects of anabolic-androgenic steroids and growth hormone as commonly used sport supplements on the kidney: a systematic review. *BMC Nephrol* 2019; 20: 198. 2019/06/04. DOI: 10.1186/s12882-019-1384-0.
13. Tarashande Foumani A and Elyasi F. Oxymetholone-Induced Acute Renal Failure: A Case Report. *Caspian J Intern Med* 2018; 9: 410-412. DOI: 10.22088/cjim.9.4.406.
14. Okubo K, Kurosawa M, Kamiya M, et al. Macrophage extracellular trap formation promoted by platelet activation is a key mediator of rhabdomyolysis-induced acute kidney injury. *Nat Med* 2018; 24: 232-238. 2018/01/09. DOI: 10.1038/nm.4462.
15. Karrow NA, McCay JA, Brown R, et al. Oxymetholone modulates cell-mediated immunity in male B6C3F1 mice. *Drug Chem Toxicol* 2000; 23: 621-644. 2000/11/09. DOI: 10.1081/dct-100101974.
16. Nejati V, Zahmatkesh E and Babaei M. Protective Effects of Royal Jelly on Oxymetholone-Induced Liver Injury in Mice. *Iran Biomed J* 2016; 20: 229-234. 2016/05/15. DOI: 10.7508/ibj.2016.04.007.
17. Nejati V, Gholamreza N, N H, et al. *Effect of Oxymetholone on Spermatogenic Indices in Rats*. 2019.

18. Rahmanian S, Johari H, Jahromi V, et al. Effect of maternal drug treatment during pregnancy and lactation oxymetholone through the levels of sex hormones in adult female offspring rats. *Advances in Environmental Biology* 2012; 6: 2791-2795.
19. NTP Toxicology and Carcinogenesis Studies of Oxymetholone (CAS NO. 434-07-1) in F344/N Rats and Toxicology Studies of Oxymetholone in B6C3F1 Mice (Gavage Studies). *National Toxicology Program technical report series* 1999; 485: 1-233. 2003/02/07.
20. Fujifilm. FUJI DRI-CHEM SLIDE TP-PIII. 2014.
21. Muhammad-Azam F, Nur-Fazila SH, Ain-Fatin R, et al. Histopathological changes of acetaminophen-induced liver injury and subsequent liver regeneration in BALB/C and ICR mice. *Veterinary world* 2019; 12: 1682-1688. 2019/11/04. DOI: 10.14202/vetworld.2019.1682-1688.
22. Al Asmari AK, Al Sadoon KT, Obaid AA, et al. Protective effect of quinacrine against glycerol-induced acute kidney injury in rats. *BMC nephrology* 2017; 18: 41-41. DOI: 10.1186/s12882-017-0450-8.
23. Ahmed,O.H.(2018). Histological Effect of Androgenic Anabolic Steroide Dianabol in
24. **Heart and Some Blood Parameters of Male Albino Rats**. .J.Global Pharma Tech. **10(03): 215-219**