

**EVALUATION THE EFFECT OF ORAL COLLAGEN-A® SUPPLEMENTATION ON THE HEPATIC AND RENAL FUNCTIONS IN MATURE MALE RABBITS**

**Nawras A. ALWAN**<sup>1</sup>

University Basrah, Iraq

**Sinaan Th. ABDULLAH**

University Mosul, Iraq

**Eman Aboud AL-MASOUDI**

University Basrah, Iraq

**Abstract:**

Collagen is the main structural protein of connective tissues in animals. Comprising approximately 30% of all proteins in the body, it is present in fibrous tissues, such as tendons and ligaments, as well as in the cornea, cartilage, bones, skin, and blood vessels. This study was aims to evaluation the effect of oral administration of collagen- $\alpha$ ® on the health status of functions of liver and kidneys in male rabbits. The animals were randomly (6 rabbits/group) divided into three groups which include: Group-A (standard group) was administered with 1 ml of distal water, Group-B (collagen- $\alpha$ 15) was administered with 1 ml of collagen- $\alpha$ ® and Group C (collagen - $\alpha$ 30) was administered with 1ml of Collagen- $\alpha$ ® for 30 days. The results showed various changes in parameters and histopathology that related to the liver and kidneys functions in groups of collagen- $\alpha$  when compared with the control group. The risk of sub-acute and acute toxic effect was observed in mature male rabbit's oral administration with 1 ml collagen- $\alpha$  supplement for 30 days. This result suggests that the adverse effect of collagen derived supplements administration for long period.

**Keywords:** Collagen-A®, Hepatic, Renal, Mature Male.

---

 <http://dx.doi.org/10.47832/2717-8234.14.14>

<sup>1</sup>  [nawras.alwan@uobasrah.edu.iq](mailto:nawras.alwan@uobasrah.edu.iq), <https://orcid.org/0000-0001-8101-2545>

## Introduction:

Collagen is considered one of the most beneficial prebiotics due to its low immunogenicity and high biocompatibility; also it has been extensively studied as a polymer that is used in many biomedical products such as cosmetics and pharmaceutical products (1). Nowadays, the biomolecule can be obtained by extraction from natural sources such as plants and animals or by recombinant protein production systems including yeast, bacteria, mammalian cells, insects or plants, or artificial fibrils that mimic collagen characteristics like the artificial polymer commercially named as KOD. Due to its growing use, the market size is estimated to be worth over USD 6.63 billion by 2025 [Collagen Market by Source (Bovine, Swine, Poultry, Marine), Product (Gelatin, Hydrolyzed Collagen), Application (Food & Beverage, Healthcare, Cosmetics), by Region, and Sectoral Forecasts, 2014–2025(2)]. Collagen is the most abundant protein in the human and animal body that has many multi-functions. The loss or defect of collagen can cause skin aging and other diseases and also increase of collagen. The collagen treatments have demonstrated effective improvements in skin hydration, skin elasticity and medical scaffold treatment in many clinical studies. In addition, the collagen treatment for GERD in COVID-19 patients. Collagen therapy can reach good improvement and does not cause any serious adverse reactions. Collagen-based materials and products are the potential to be used in more applications, and they are the one of most important supplements for aging people (3).

Collagen (CH) intake has an effect on the absorption and metabolism of lipid and glucose. CH significantly reduces high fat diet-induced body weight gain and down regulates serum levels of total cholesterol, triglyceride and low-density lipoprotein (4) and alter lipid metabolism-related gene expression and the unfolded protein response in mouse liver (5). The hypoglycemic effects of CH have also been reported (6). It has been reported that CH can improve glucose tolerance by inhibiting intestinal glucose uptake and enhancing insulin secretion, suggesting the antidiabetic property of CH (7). Previous studies have revealed that CH-II reduced lameness pain and pain during limb manipulation, and physical exertion in arthritic (8). A high risk of chronic toxic effect was observed in pregnant rabbits inoculated with 1 ml of oral dose of collagen alpha supplement (9). The current study was designed to evaluate the effects of Collagen- $\alpha$ <sup>®</sup> as a dietary supplement on hepatic and renal functional changes in healthy adult male rabbits.

## Materials and Methods:

### Experimental design:

Eighteen mature male rabbits (*Lepus cuniculus*) (weight 1000-1200 gm) were housed under controlled environmental conditions in Veterinary Animal House, from 1/2/2021 to 6/7/2021 in College of Veterinary Medicine/University of Basrah, Basrah. The rabbits were randomly divided into three groups (6 animals/group) ;

- 1- G A (control group) were orally administrated with 1 ml of distal water.
- 2- G B (CH- $\alpha$  15) were administration orally 1 ml of collagen- $\alpha$ <sup>®</sup> by gavage for 15 days.
- 3- G C (CH- $\alpha$  30) were administration orally 1 ml/animal of collagen- $\alpha$ <sup>®</sup> by gavage for 30 days.

**Collagen- $\alpha$  source and dosage: each ampulla contain 10 ml of Collagen Peptide (5g), Rosehip Extract (0.5g) and Vitamin-C (60mg), dosage 1ml/kg BW) (10).**

Collection of blood samples (10 ml) via the cardiac puncture of animals by using 5ml sterile syringe and then putting in tubes without anticoagulant and then serum isolation by using centrifugation (3000 rpm / 15 min), stored it at -20°C until analysis and then sacrificed the animals to take liver and kidneys (after 15 and 30 days) for histopathological examination.

**Biochemical Measurements:** Some biochemical measurements were done on the serum after separation by using special enzymatic kits as follow:

**1-Serum Aspartate aminotransferase (AST) Estimation(U/I) and Serum Alanine aminotransferase (ALT) Estimation(U/I):** Aspartate and alanine aminotransferase is measured by monitoring the concentration of oxaloacetate hydrazone formed with 2,4-dinitrophenyl-hydrazine (11).

**2-Serum Alkaline Phosphatase (ALP) Estimation(U/I):** This estimation was done by using the colorimetric determination of alkaline phosphatase activity (12).

**3-Total Protein Measurement:** Colometric method described by Young, (12) and Titez, (13). By using the biuret reagent contains sodium potassium tartrate to complex cupric ions and maintain their solubility in alkaline solution

**4- Urea Measurement :** Urea is hydrolyzed in the presence of water and urease to produce ammonia and n dioxide (14).

**5- Serum CreatinineMeasurment:** Creatinine is endogenously produced and released to body fluids at a stable rate and its plasma and serum levels are maintained within narrow limits, it can be measured as an indicator of glomerular filtration rate (GFR) (15).

**6-Serum Malondialdehyde measurements (MDA):** The main end product of lipid peroxidation is Malondialdehyde, will be carried out in serum according to Yagi method (16).

Histological examination: Liver and kidney were cut immediately, weighed, and fixed (in 10% formalin solution) for 24 hours. Samples were dehydrated through a graded series of ethanol and xylene before paraffin-embedding and staining with hematoxylin and eosin stains (17).

**Statistical Analysis:** The results were expressed as mean ± standard deviation (M±SD), the data of experiment analyzed by using One-way ANOVA by SPSS (Special Program for Statistical System) version 21.0. The least significant difference test (LSD) was used to determine the differences between groups in ANOVA-test, the level significant set on p< 0.05 (18).

**Results:**

**Organs weight:**the weight of liver and kidneys showed in table (1) revealed the weights of organs, that showed significant (P≤0.05) decreased in liver, kidneys weights in groups B and C treated with collagen-α® as compared to control group.

**Table (1): effect of collagen-α® on organs weights of mature male rabbits:**

Groups	Liver weight(gm)	Kidney weight(gm)
GA (Standard)	70.39 ±5.62 <sup>A</sup>	8.63±1.20 <sup>A</sup>
GB (collagen-α® 15)	58.63±5.73 <sup>A</sup>	6.99±0.75 <sup>A</sup>
G C(collagen-α® 30)	52.67±3.93 <sup>B</sup>	6.52±0.58 <sup>A</sup>
LSD	12.52	1.32

Capital-letters denote to significant differences at level (P < 0.05) (M ± S D).

**Effect of collagen-α® on serum liver enzymes and MDA in adult male rabbits:** The effects of collagen-α® for 15 and 30 days on liver enzymes (include: ALT, AST and ALP) and MDA enzymes revealed in table (2), these results of these enzymes increased significant (P≤0.05) in group C more than other groups and also in G B significantly (P≤0.05) elevation more than control group but less than G-C. Also MDA concentration increment significantly (P≤0.05) in G-C and GB compared to control group.

**Table (2): Effect of collagen-α® on serum liver enzymes and MDA concentrations in mature adult male rats (M±SD.): (n=6)**

Parameters Groups	ALT (U/l)	AST (U/l)	ALP (U/l)	MDA (U/l)
GA(Control)	80.61±1.92 <sup>c</sup>	83.91±0.99 <sup>c</sup>	9.91±1.04 <sup>c</sup>	0.28±0.008 <sup>c</sup>
GB(CH-α® 15)	91.07±1.57 <sup>B</sup>	90.36±1.36 <sup>B</sup>	12.10±0.92 <sup>B</sup>	0.45±0.036 <sup>B</sup>
GC(CH-α® 30)	96.72±1.32 <sup>A</sup>	99.63±1.56 <sup>A</sup>	14.09±1.38 <sup>A</sup>	0.56±0.023 <sup>A</sup>
LSD	5.06	4.21	2.11	0.030

Capital-letters denote to significant differences at level (P < 0.05) (M ± S D).

**Effect of collagen- $\alpha$ <sup>®</sup> on serum total protein, urea and creatinine concentrations in mature male rats:** The data in table (3) revealed the serum total protein concentration that significant difference was observed between all groups compared with control. Serum total protein (TP), urea and creatinine concentrations showed increased significantly ( $P \leq 0.05$ ) in GC more than GA and GB, also showed these parameters elevation in GB significantly ( $P \leq 0.05$ ) more than Standard group.

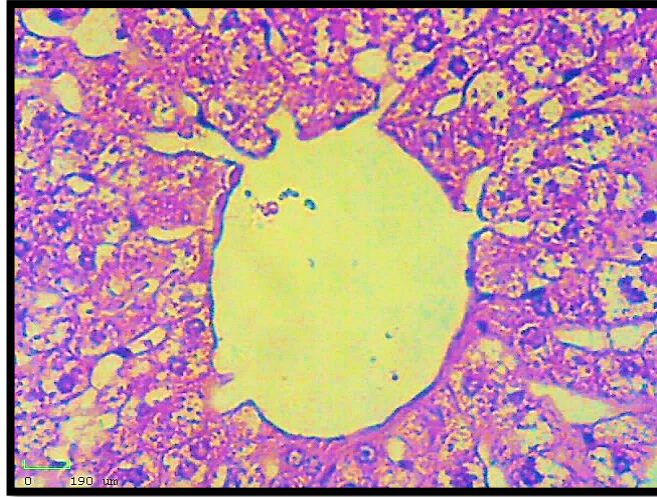
**Table (3): Effect of collagen- $\alpha$ <sup>®</sup> on serum total protein, urea and creatinine concentrations in mature male rats (M $\pm$ SD): (n=6)**

Parameters Groups	TP gm/l	Urea mg/dl	Creatinine Mbn kg/l
GA(Control)	6.30 $\pm$ 0.53 <sup>c</sup>	42.39 $\pm$ 4.86 <sup>c</sup>	3.79 $\pm$ 0.73 <sup>c</sup>
GB( collagen- $\alpha$ <sup>®</sup> 15)	8.05 $\pm$ 0.61 <sup>B</sup>	76.55 $\pm$ 5.69 <sup>B</sup>	5.91 $\pm$ 0.91 <sup>B</sup>
G C( collagen- $\alpha$ <sup>®</sup> 30)	9.34 $\pm$ 0.55 <sup>A</sup>	90.88 $\pm$ 7.32 <sup>A</sup>	8.21 $\pm$ 1.38 <sup>A</sup>
LSD	1.25	11.37	2.67

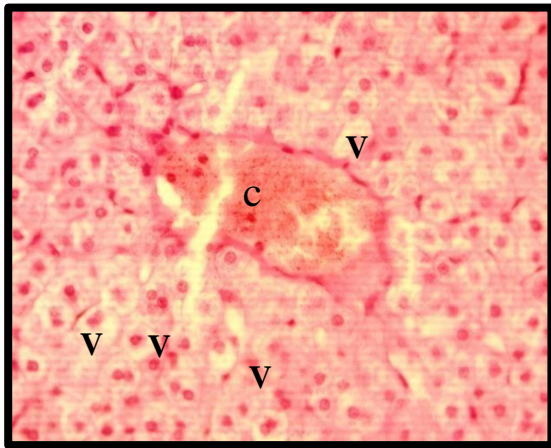
Capital-letters denote to significant differences at level ( $P < 0.05$ ) (M  $\pm$  S D).

#### Histopathological Examination:

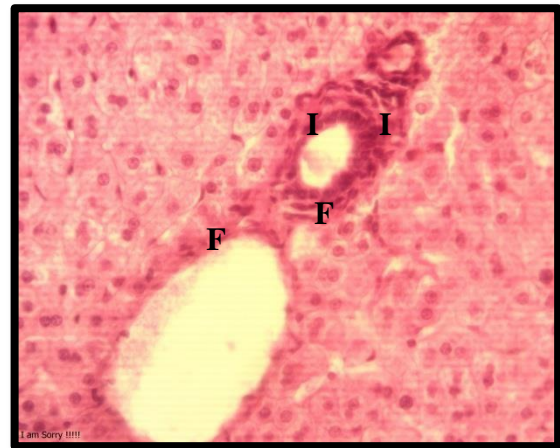Fig. (1) The section in the liver of control group showing normal hepatocytes, sinusoids emptied into a clear central vein, hepatocytes radiate as hepatic plates from central veins, Fig (2) histological section in liver group B (CH- $\alpha$ <sup>®</sup>15) showed congestion of central vein and vacuolation in hepatocytes (pericentral vacuolation), Fig (3) showed the histological section of liver group II (CH- $\alpha$ <sup>®</sup>15) showed per-biliary duct infiltration of inflammatory cells as well as market degree of early fibrosis, Fig (4) histological section in liver G C (CH- $\alpha$ <sup>®</sup>30) showed mild congestion of central vein and vacuolation in hepatocytes (pericentral vacuolation). Fig (5) showed Histological section in liver G C (CH- $\alpha$ <sup>®</sup>30) sever congestion of per-biliary duct and infiltration of inflammatory cells as well as market degree of early fibrosis. Fig (6) histological section of kidney of group A (control) showed normal architecture of renal parenchyma, Fig (7) Histological section in kidney group B(CH- $\alpha$ <sup>®</sup>15) showed hyperplasia of mesangial cells and moderate vacuolation of renal tubules, Fig (8) Histological section in kidney in group B (CH- $\alpha$ <sup>®</sup>15) showed atrophy of glomerulus, in addition to moderate vacuolation and dilation renal tubules. Histological section in kidney group C (CH- $\alpha$ <sup>®</sup>30) showed in fig (9) appeared the glomerular atrophy and dilation of glomerular space and vacuolation of renal tubules while Fig (10) showed the histological section of kidney in G C (CH- $\alpha$ <sup>®</sup>30) showed mesangial cells hyperplasia.



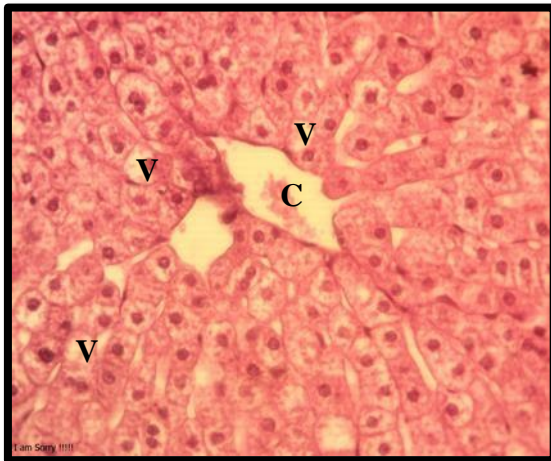
**Fig. (1) Histological section in liver of group A (standard group) showed normal appearance of hepatic parenchyma and tissue (H&E stain 400X).**



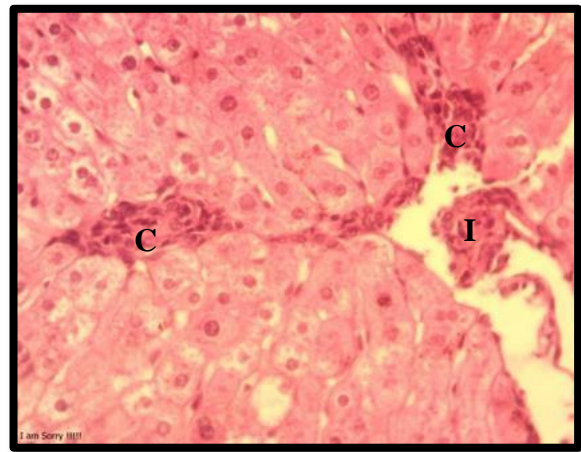
**Fig(2):** Histological section in liver group B (collagen- $\alpha$ 15) showed congestion (C) of central vein and vacuolation (V) (H&E stain 400X).



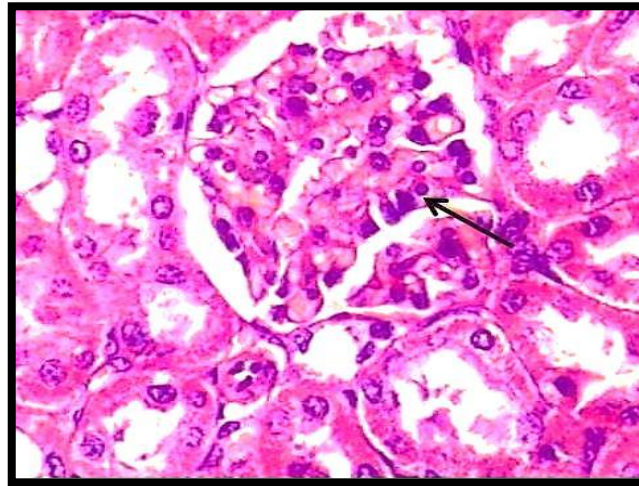
**Fig (3):** Histological section in liver group B (collagen- $\alpha$ 15) showed per-biliary duct infiltration of inflammatory cells (I) as well as marked degree of early fibrosis (F) (H&E stain 400X).



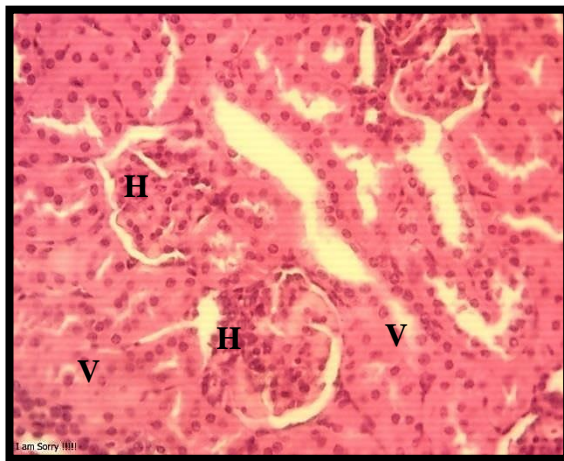
**Fig (4):** Histological section in liver group C (collagen- $\alpha$ 30) showed mild congestion (C) of central vein and vacuolation (V) in hepatocytes (pericentral vacuolation) (H&E stain 400X).



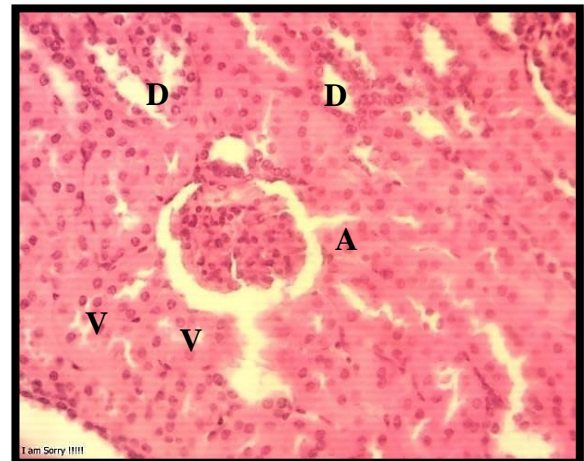
**Fig (5):** Histological section in liver group C (collagen- $\alpha$ 30) showed severe congestion (C) of per-biliary duct and infiltration (I) of inflammatory cells as well as marked degree of early fibrosis (H&E stain 400X).



**Fig (6) Histological section of kidney of group A (Standard) showed normal architecture of renal parenchyma (H&Estain400 X)**

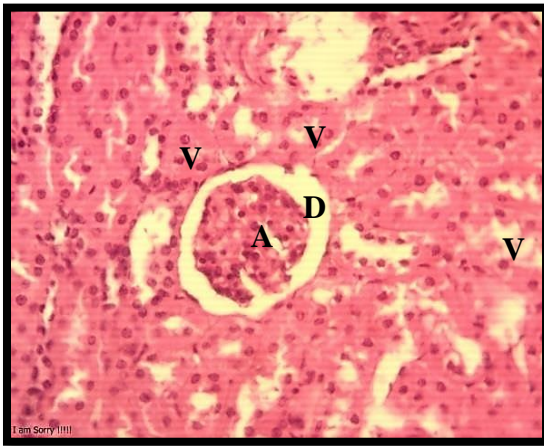


**Fig (7): Histological section in kidney group B (collagen- $\alpha$ 15) showed hyperplasia of mesangial cells (H) and moderate vacuolation of renal tubules (V) (H&E stain 400X).**

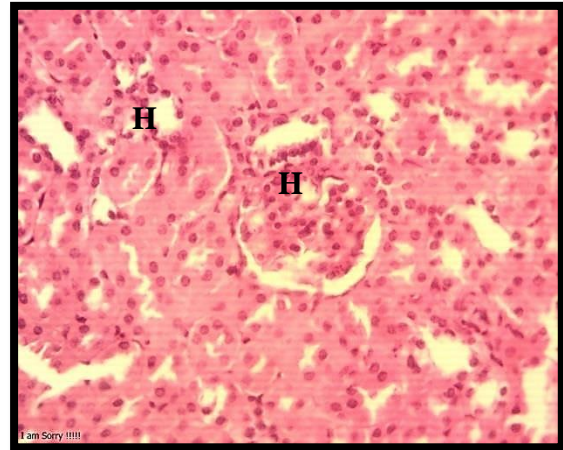


**Fig(8):Histological section in kidney group B (collagen- $\alpha$ 15) showed atrophy of glomerulus (A), in addition to moderate vacuolation (V) and dilation renal tubules (D) (H&Estain400X).**





**Fig (9):** Histological section in kidney group C (collagen- $\alpha$ ®30) showed glomerular atrophy (A) and dilation of glomerular space (D) and vacuolation of renal tubules (V) (H&E stain 400X).



**Fig (10):** Histological section in kidney group C (collagen- $\alpha$ ®30) showed hyperplasia (H) of mesangial cells H&E stain 400X).

### Discussion:

Little is known about the role of collagen defect as a source of disorder in both humans and animals in Iraq threatening its use in providing food in daily life as well as the chronic toxic effects of these products. The collagen- $\alpha$ ® supplements are known as safe for human consumption by FDA in USA (19) which that deposited it has low risk on healthy status but little researches are a valuable, one of these clinical application of collagen- $\alpha$ ® is treatment of skin and cartilage disorders and therefore little information about effect of this supplement effects on healthy status and toxicity effects on different organs and physiological parameters, therefore this study to demonstrate the effects of collagen- $\alpha$ ® on healthy status and different organs were done.

In this study, we reported decreased in liver and kidneys weights, these may be due to its acts as anti-obesity by its regulation metabolism of lipids and proteins and also may be suggested its effects on appetite centers in the brain (20). These changes in the liver, and kidneys weights agreement with that reported by Kudayer *et al.* (9) who noted that used 1 ml of CH- $\alpha$ ® supplementation for pregnant rabbits for 30 days have adverse effect on liver and kidney weights and its functions and also signed to changes negatively in body weight and BW gain. The histological changes recorded in figures of liver and kidneys related to the changes in body, organs weights and BW changes and similar to that reported by Kudayer *et al.* (9) that notes increase in elasticity of muscles but decrease in muscle mass. Like other types of animal protein, collagen contains a type of amino acid called hydroxyproline (21). Hydroxyproline is converted into oxalate in body, which may increase levels of oxalate excretion in urine (22). In one older study, consuming 30 grams of gelatin derived from collagen increased urinary oxalate excretion by 43% after 24 hours compared with a control group (23). Several animal studies also show that consuming high amounts of hydroxyproline could increase oxalate levels in the urine, and therefore, may harm kidney health (24). Other test of animal studies suggest that these effects could be amplified in those with primary hyperoxaluria, a genetic disorder that affects oxalate metabolism and increases the risk of recurrent kidney stones. However, keep in mind that most of these studies used concentrated amounts of hydroxyproline. Therefore, it's unclear how the

collagen found in meat or supplements may affect urinary oxalate excretion and kidney stone formation when consumed in normal amounts (25, 26). Also the results in table 3 revealed elevations in total protein, urea and creatine concentration that explain the effect of collagen on kidney function and also which supported by histopathological changes in kidneys tissues (fig. 7, 8, 9 and 10). It is also important to remember that taking collagen for a specific problem such as improving your skin, relieving joint pain, or maintaining muscle does not work. We cannot determine how the body uses the amino acids in food or supplements. Therefore, there is no reason to believe that taking a dietary supplement is better than eating healthy food (27). The serum MDA test is the most widely used method in clinical practice due to its sensitivity and simplicity, although many substances interfere with this test. MDA results primarily from the oxidative degradation of polyunsaturated fatty acids (PUFAs). MDA are a product of lipid peroxidation in cell membranes as a result of the interaction of PUFAs and free radical species (28). Therefore elevation of this product indicates for generation of free radicals from long exposure to collagen.

**References:**

1. Sionkowska, A., Adamiak, K., Musiał, K., &Gadomska, M. (2020). Collagen based materials in cosmetic applications: A review. *Materials*, 13(19), 4217.
2. Holmes, D. F., Lu, Y., Starborg, T., &Kadler, K. E. (2018). Collagen fibril assembly and function. *Current topics in developmental biology*, 130, 107-142.
3. Wang, H. (2021). A review of the effects of collagen treatment in clinical studies. *Polymers*, 13(22), 3868.
4. Tang L, Sakai Y, Ueda Y, Katsuda S (2015) Effects of oral administration of tripeptides derived from type I collagen (collagen tripeptide) on atherosclerosis development in hypercholesterolemic rabbits. *J. BiosciBioeng.*; 119(5): 558-563.
5. Lee EJ, Hur J, Ham SA, Jo Y, Lee S, et al. (2017) Fish collagen peptide inhibits the adipogenic differentiation of preadipocytes and ameliorates obesity in high fat diet-fed mice. *Int J BiolMacromol* 104: 281-286.
6. Tometsuka C, Koyama YI, Ishijima T, Toyoda T, Teranishi M, et al. (2017) Collagen peptide ingestion alters lipid metabolism-related geneexpression and the unfolded protein response in mouse liver. *Br J Nutr.*; 117(1): 1-11.
7. Zhang R, ChenJ, Jiang X, Yin L, Zhang X (2016) Antioxidant and hypoglycaemic effects of tilapia skin collagen peptide in mice. *Int J Food Sci* 51(10): 2157-2163.
8. Gencoglu, H., Orhan, C., Sahin, E., &Sahin, K. (2020). Undenatured type II collagen (UC-II) in joint health and disease: a review on the current knowledge of companion animals. *Animals*, 10(4), 697.
9. Kudayer, A. M., Alwan, N. A., &Sawad, A. A. (2020). A Chronic Toxicity Study of Oral Administration of Collagen- $\alpha$ ® Supplement using Pregnant Rabbits. *Indian Journal of Forensic Medicine & Toxicology*, 14(3), 931.
10. Kudayer, A. M., Alwan, N. A., & Sawad, A. A. (2020). A Chronic Toxicity Study of Oral Administration of Collagen- $\beta$ ® Supplement using Pregnant Rabbits. *Indian Journal of Forensic Medicine & Toxicology*, 14(3), 930-935.
11. Schumann, G. and Klauke, R. (2003). New IFCC reference procedures for the determination of catalytic activity concentrations of five enzymes in serum: Preliminary upper reference limits obtained in hospitalized subjects. *Clin. Chim. Acta*; 327(1-2): 69-79.
12. Young, R.J.C. (1995). Foucault on race and colonialism. *New Form.*; 25:57-65.
13. Tietz, N.M. (1996). *Fundamentals of clinical chemistry*. 3rd ed., W.B. Sanders Co.; Pp.:584-595.
14. Tietz, N.W. (2006). *Clinical guide to laboratory test*. 4th ed. Publ. U.S.; 638-9ET: 1062-1065.
15. Bartels, H.; Böhmer, M. and Heierli, C. (1971). Serum creatinine determination without protein precipitation. *Clin. Chim. Acta.* ; 37:193-197.
16. Yagi, K. (1998). Serum malondialdehyde measurements. *Free Rad. Antiox. Prot.*; 108:101-106.
17. Luna L.G. (1968). *Manual of histologic staining methods of the Armed Forces Institute of Pathology. Stains and Staining (Microscopy)*. 3ed.: <http://agris.fao.org/aos/records/US201300459165>. p 258
18. Abo-Allam, R.M. (2003). *Data statistical analysis using SPSS Program*. 1<sup>st</sup> ed. Publ. for the U. Cairo. Pp.: 44-50.
19. Daneault A, Prawitt J, Fabien Soulé V, Coxam V andWittrant Y. (2017). Biological effect of hydrolyzed collagen on bone metabolism. *Crit Rev Food Sci Nutr.*; 57(9): 1922-1937.
20. Woo M, Song Y, Kang KH, Noh J. (2018). Anti-Obesity Effects of Collagen Peptide Derived from Skate (*Raja kenojei*) Skin Through Regulation of Lipid Metabolism. *Mar. Drugs.*; 16(9): 306.

21. Srivastava, A.K.; Khare, P.; Nagar, H.K., Raghuvanshi, N. and Srivastava, R. (2016). Hydroxyproline: A Potential Biochemical Marker and Its Role in the Pathogenesis of Different Diseases. *Curr Protein Pept Sci.*;17(6):596-602.
22. Fargue, S.; Milliner, D.S.; Knight, J.; Olson, J.B.; Lowther, W.T. and Ross, P. (2018). HolmeHydroxyproline Metabolism and Oxalate Synthesis in Primary Hyperoxaluria. *Am. Soc. Nephrol.*; 29(6): 1615–1623.
23. Knight, J.; Jiang, J.; Assimos, D.G. and Holmes, R.P. (2006). Hydroxyproline ingestion and urinary oxalate and glycolate excretion *Kidney Int.*; 70(11): 1929–1934.
24. Sivalingam, J.E.; Nakada, S.Y.; Sehgal, P.D.; Crenshaw, T.D. and Penniston, K.L. (2013). Dietary hydroxyproline induced calcium oxalate lithiasis and associated renal injury in the porcine model. *Epub.*; 27(12):1493-1498.
25. Li,X.; Knight, J.; Fargue, S.; Buchalski, B.; Guan,Z.; Inscho, E.W.; Liebow, A.; Fitzgerald, K.; Querbes, W.; Lowther,W. T. and Holmes, R.P. (2017). Metabolism of <sup>13</sup>C5-hydroxyproline in mouse models of Primary Hyperoxaluria and its inhibition by RNAi therapeutics targeting liver glycolate oxidase and hydroxyproline dehydrogenase. *Biochim. Biophys. Acta.*; 1862(2): 233–239.
26. Wang, H. (2021). A review of the effects of collagen treatment in clinical studies. *Polymers*, 13(22), 3868.
27. Underferth, D. (2021). Should I take a collagen supplement?. <https://www.mdanderson.org/etc.clientlibs/mda/clientlibs/mda-web/clientlib-site/resources/images/xmda-logo.png.pagespeed.ic.ciGH9dxNVR.webp>.
28. Fritz, K.S.; Petersen, D.R. (2013). An overview of the chemistry and biology of reactive aldehydes. *Free Radic.Biol. Med.*, 59, 85–91