

APPLICATIONS OF CURCUMIN EXTRACT FORMULATIONS FOR THE HEALING EFFICACY ON MICE WOUNDS

Awatif I. MUHAMMED¹

Corporation of Industrial Research, Iraq

Ban Sahib Abdul-Nabi AL- NASIRY²

University of Baghdad, Iraq

Aseel M.H.Abed AL-RUDHA³

University of Baghdad, Iraq.

Mohammed M. DAKHEEL⁴

University of Baghdad, Iraq

Safaa ALI⁵

Corporation of Industrial Research, Iraq

Abstract

This study aimed to evaluate the antibacterial activity of various formulations of alcoholic extracts of *Curcuma longa* (Curcumin) on *Staphylococcus aureus* and *E. coli* in wounds injured mice compared to the action of the extracts with clotrimazole antibiotic. Using the well agar diffusion technique, *in vitro* bactericidal activity of curcumin alcoholic extract was established against several pathogens. Curcumin extract and clotrimazole ointment was also made from a combination of extract and antibiotics to examine how different formulas affected injured skin in mice. 25 albino mice were divided into five groups and had their skin incised and treated in various ways. *In vitro* experiments against *E. coli* and *Staphylococcus aureus* revealed excellent potency through the zone of inhibition. Furthermore, *in vivo* findings of the groups given therapeutic doses of extracts revealed significant values in treatment and a reduction in clinical signs, as well as notable, exceeds of the results of the extract oily ointment at (2.5 % w\v) compared to (5 % w\w), as well as similar results between curcumin extract oily ointment (2.5 %) and curcumin extract and clotrimazole oily ointment (2.5 %) groups, at significant differences. Histopathological investigations of the groups (G2, G3, G4, and G5) that had outstanding wound healing with normal skin in varying degrees compared to the control group supported these findings (G1). Curcumin alone or combined with clotrimazole as oily formula at concentration (2.5%) show augmented wound healing efficacy compared to formula at concentration (5%) after 15days of treatment, The skin section show excellent collagen deposition with enhanced re-epithelialization regeneration. at the 7 day of treated, curcumin formula at concentration (5%) exhibited lower fibroblast and fibrocystic distribution and less infiltration of cells in

 <http://dx.doi.org/10.47832/2717-8234.11.20>

1  muhammedawatif@gmail.com

2  ban.sn62@covm.uobaghdad.edu.iq, <https://orcid.org/0000-0002-3349-4153>

3  aseel.mh123@covm.uobaghdad.edu.iq

4  m.m.dakheel@covm.uobaghdad.edu.iq, <https://orcid.org/0000-0002-1938-8098>

5  SafaaAli@gmail.com

tissue compared to curcumin formula at concentration (2.5%) and control which show up-regulated neovascularization with highly fibroblast presence.

In conclusion, the current study demonstrated the efficacy of using an alcoholic extract (Curcumin) as a special formula in combination with the antibiotic clotrimazole to show high potential uses in wound skin healing in mice; additionally, use inefficiently retarding and preventing bacterial infections such as *E. coli* and *S. aureus*.

Keywords: Curcumin Extract, Clotrimazole, Antibacterial Activity, Histopathology, *Staphylococcus Aureus*, *E. Coli*.

Introduction



Curcuma longa; Is a ginger-family plant that has been used as herb and conventional remedy in India and China for centuries to cure hepatocellular illnesses, coughs, diabetic ulcers, and rheumatic ailments [1]. Curcumin has been shown in many researches to have antioxidant, anti-aging, anti-inflammatory, immunomodulatory, wound healing, anti-tumour, and anti-psoriatic properties [2-4]. Inflammation, proliferation or (granulation), and maturation are the three steps of the wound healing process [5]. Alternative plants have been used in various studies for wound repair due to therapeutic

benefits such as flavonoids, essential oils, alkaloids, phenolic compounds, terpenoids, and fatty acids [6,7], as well as cheap cost, few harmful activities, bioavailability, and effectiveness [8,9]. Clotrimazole is a chemical imidazole compound with wide antimycotic action that works by inhibiting fungal cell membrane production. This is used to cure local candidiasis, fungal diseases on the skin such ringworm, and jock itch. The semisolid method improved medication dispersion and bioavailability by increasing the solubility of poorly water-soluble substances [10]. Additionally, increase their efficiency by incorporating them into structures since materials with high surface areas tend to change their physical and chemical properties [11-12]. The purpose of this study was to see how different formulations of curcumin extract affected the healing of wounds in mice as an animal model. Healing is a complicated process that includes inflammation, granulation, and tissue remodelling; as a result, several elements have been discovered to have a role in delaying the mending process, such as oxygen-free radicals [13]. As a result, using materials high in antioxidant defence can reduce healing time and speed up the process. Furthermore, several studies have chosen to utilize a mix of herbs and antibiotics in various therapeutic procedures to prevent antibiotic resistance [14]. Therefore, the present study relies on establishing the efficacy of the herbal extract in various formulas other than antibiotics in order to assess the herbal activities of formulae to treat wounds.

Materials and methods

Preparation of curcumin extract

The plant powder of curcumin was extracted using ethanol 70% for 4 days with the maceration method (the percentage of the plant to solvent is 1/3). Every 24 hours, the solvent was renewed and the extract was concentrated under reduced pressure and Spray-dried [15]

Preparation of herbal ointment formula

In order to prepare ointment base, bees wax, liquid paraffin and Vaseline were used. Two concentrations of extract (2.5 w\% & 5 w\%) and clotrimazole (2.5 %) were added to the ointment base. While the second formula was used Curcumin extract in concentration (2.5 w\% & 5 w\%) with White soft paraffin (100ml) by using hotplate magnetic stirrer with 40°C for 1hr. according to (British Pharmacopoeia, 1988).

Antibacterial analyses by agar diffusion method

The antibacterial activity of both ointment formulation prepared was studied against gram positive bacteria (*Staphylococcus aureus*), gram negative bacteria (*Escherichia coli*). The antibacterial activity of the extracts was determined by agar well diffusion technique by using 20 ml of nutrient agar media was transferred into plate and they were left undisturbed for 1-2 h. Bacterial culture (0.5 µl) was transferred into plate using cotton stick and spread with sterile glass rod and made holes with 6 mm diameter for each concentration added into well. Then plates incubated for 37 °C 24 h then the antibacterial activity was determined by measuring the zone inhibition around each well [16].

In vivo evaluation of wound healing

The study was achieved using (25) Albino mice (weighted 27.5 ±150 g) that were housed in standard plastic cages with stainless steel coverlids; moreover, wheat straw was used as bedding material. The animals were kept at the AL-Razi Research Centre's animal house. Pellets and water were freely available to these animals. The temperature is maintained constant at 25°C with a relative humidity of 50–60%. The animals were placed in polypropylene cages with sterilized rice husk bedding and a 12-hour light/12-hour dark cycle; afterwards, the experiment was ended with the histopathological analysis for the treated skin. The animals were divided into five groups; each group consisted of 5 animals, as follows:

Group 1 – Excision wounded animals without treatment

Group 2 – Excision wounded animals with curcumin extract (2.5% w\%) oily ointment.

Group 3 – Excision wounded animals with curcumin extract (2.5% w\%) and clotrimazole (2.5% w\%) oily ointment

Group 4– Excision wounded animals with curcumin extract (5% w\%) ointment

Group 5– Excision wounded animals with curcumin extract (5% w\%) oily ointment

Statistical analysis: All data of the present study are expressed as mean ± standard error of mean (S.E.M.) of five animals. Data were analysed by two-way analysis of variance (ANOVA) followed by Bonferroni's post-test using the GraphPad Prism Version 5.0 software program (GraphPad Software, San Diego, CA, USA). A value of $p < 0.05$ was considered statistically significant [17].

Results and discussion

Curcumin extract formulations prepared have shown excellent potency against gram-positive (*S. aureus*) and gram-negative (*E. coli*). In *S. aureus* the zone of inhibition was 5mm of curcumin extract ointment (2.5%), 12mm of extract and clotrimazole ointment (2.5%), 30mm of extract oily ointment (2.5%), 33mm of extract and clotrimazole oily ointment (2.5%), 15mm of extract ointment (5%) and 17mm of extract oily ointment (5%). While the results in gram-negative (*E. coli*) were the zone of inhibition was 14mm of curcumin extract ointment (2.5%), 15mm of extract and clotrimazole ointment (2.5%), 33mm of extract oily ointment (2.5%), 33mm of extract and clotrimazole oily ointment (2.5%), 18mm of extract

ointment (5%) and 22mm of extract oily ointment (5%). The antibacterial activity of *C. longa* extract in the different formulas was great due to many constituents who possess potent antibacterial activity against a wide range of bacteria [18,19]; as shown in Figures (1 and 2) and table (1).

Figure (1): Inhibitory activity of curcumin in different formulation; F1 (curcumin and clotrimazole oily ointment 2.5%w\ v); F2 (curcumin oily ointment 2.5%w\ v), F1 (curcumin and clotrimazole ointment 2.5%w\ w), F2 (curcumin ointment 2.5%w\ w) on *E.coli* and *S .aureus*.

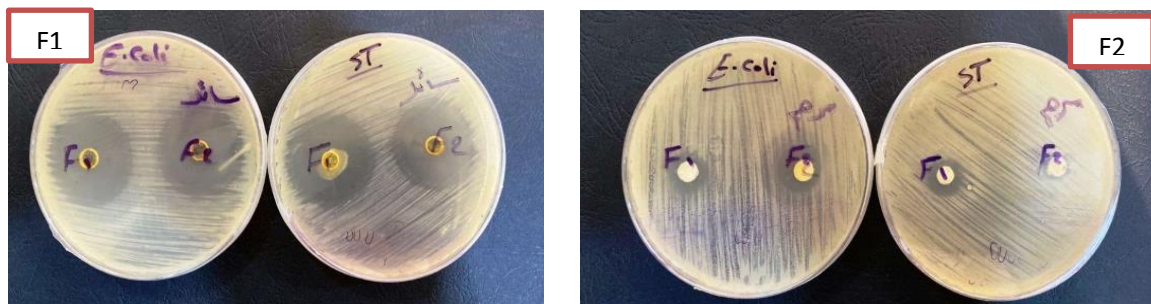

Figure (2): Inhibitory activity of curcumin extract in F1 (curcumin oily ointment 5% (w\ v) and F2 (curcumin ointment 5% w\ w) on *E.coli* and *S .aureus*.

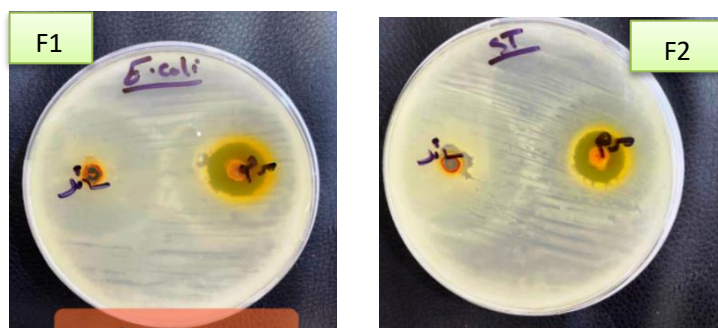


Table (1): Inhibition zone of different curcumin extract formulations against *S. aureus* and *E. coli*.

Type of ointment	Type of bacteria (mm)	
	<i>S. aureus</i>	<i>E. coli</i>
Curcumin extract ointment at concentration (2.5%) w\ w	5 ±0.21	14 ±0.11
Curcumin extract and clotrimazole ointment at concentration (2.5%) w\ w	12 ±0.14	15 ±0.13
Curcumin extract oily ointment at concentration (2.5%)w\ v	30 ±0.09	33 ±0.08
Curcumin extract and clotrimazole oily ointment at concentration (2.5%) w\ v	33 ±0.08	33 ±0.07
Curcumin extract ointment at concentration (5%) w\ w	15 ±0.12	18 ±0.13
Curcumin extract oily ointment at concentration (5%) w\ v	17 ±0.10	22 ±0.12

The result statistically significant compared with other and P-values were calculated by student's t-test and values indicated (n=5) plus stander error (SE). *P<0.05.

In the current study found that curcumin extract, particularly oily curcumin extract, had strong antibacterial activity whether taken alone or in combination with other antibacterial such as clotrimazole against Gram-positive and negative bacteria. Due to the tremendous potential of therapeutic plants compared to chemicals, safer material, and cheap cost-effectiveness, researchers have recently begun to employ them in chemistry, biology, and medicine [20]. Clotrimazole is thought to have high antibacterial and antimicrobial action [21], as well as a significant surface area to volume ratio, chemical stability, and antifungal properties [22]. As a result, the herbal extract in combination with clotrimazole has a significant potential for wound healing as well as inhibiting and preventing bacterial infections ineffectively [23]. Curcumin can heal wounds and is ineffective in delaying and avoiding infectious diseases. In a recent study, the addition of curcumin in preparation techniques was found to reduce bacterium activity, regulate microbe invasion, and follow bacterial growth [24]. Thus, *in vivo* treatment of mice with curcumin was able to successfully manage adhesion and significantly minimize injured areas [25]. Furthermore, a new extract formula accelerated wound healing, increased wound contraction rate, completely re-epithelialized the epidermis, reduced scars after therapies, and down-regulated the quality of Inflammatory cell infiltration as well as to boosting tissue recovery and collagen formulation rate [26]. Curcumin extract oily show highly antibacterial activity when used alone and combined with other antibacterial against gram-positive and negative bacteria.

Study included an examination of the application on laboratory animals albino mice by induced an external wound on the skin and treatment by application until recovery. During the time, the application observed efficiency of treatment with no side effects beside easily of using. The study involved histopathological analyses of mice skin after 7 days and 15 days to observe the tissue changes that occurred during the treatment period as in figure (3).

Figure (3): Morphological section of treated mice skin with the different formulations: a. curcumin extract ointment (5%), b. curcumin extract oily ointment (5%), c. curcumin extract oily ointment (2.5%), d. curcumin extract and clotrimazole oily ointment (2.5%), e. control group.

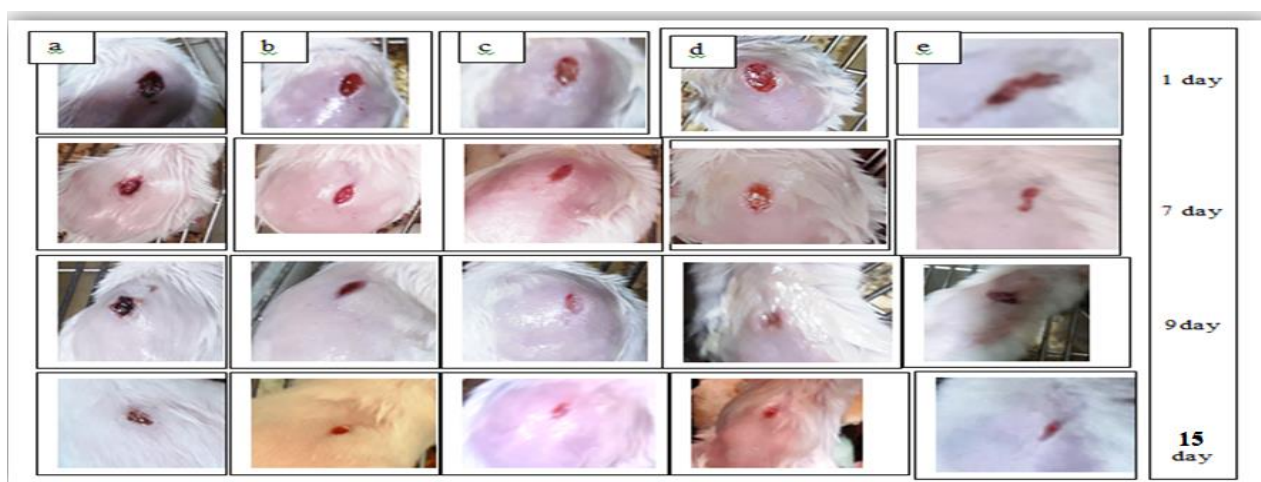
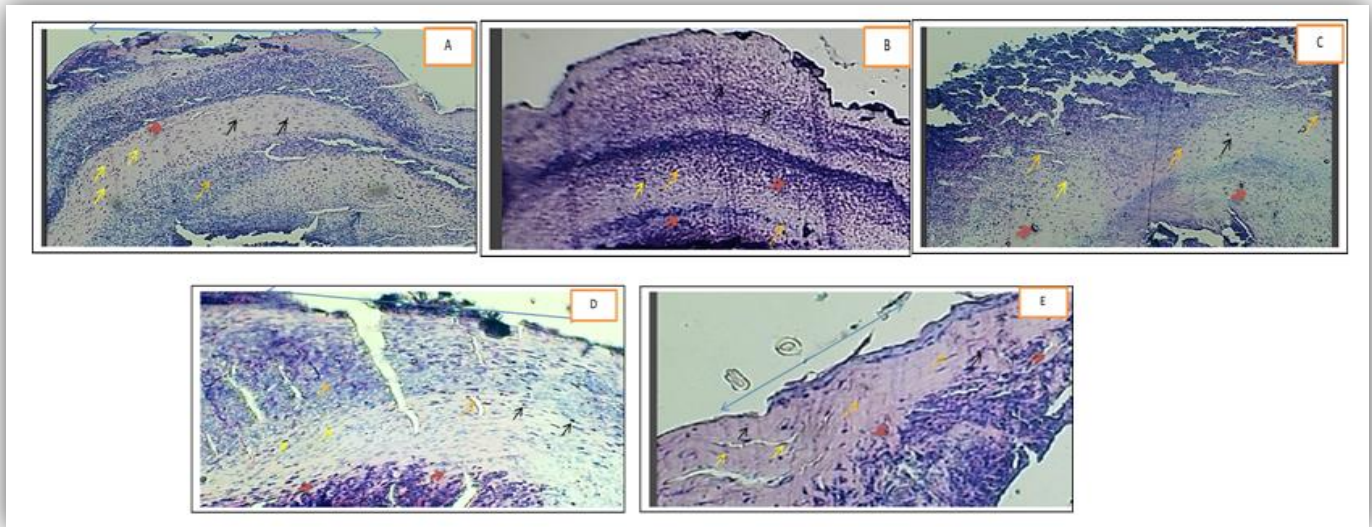


Figure (4): Histology of wound area stained with (H&E) after 7 days of treatment with different formulation of Curcumin extract show previous steps of wound healing. A. curcumin extract ointment (5%), B. curcumin extract oily ointment (5%), C. curcumin extract oily ointment (2.5%), D. curcumin extract and clotrimazole oily ointment (2.5%), E. control group.



The recent study; involved histological analysis of wound treated by curcumin application on day 7 and day 15; to determine the efficiency of curcumin application on healing processes in treatment period and finally after recovery period as in figure (4,5). The histopathological section of mice injured skin of different groups treated with curcumin extract formula after 7 and 15 days examined microscopically and stained by H&E with (100× magnification). In control group at 7 day the wound sections showed reserve presence of inflammatory cells (Fig. E). The skin layer exhibited slight re-epithelialization (Fig. A). Inflammatory cells present with fibroblast and blood vessel and not complete of re-epithelialized (Fig. B). While skin sections of (Fig. C, D) show fewer inflammatory cells, more new capillaries and more fibroblasts and new epithelial layer was formed with collagen fiber. The skin structures of control group in day15 show a complete epithelial layer, relatively compact collagen fiber and inflammatory cells were present (Fig. e). Wound section showed inflammatory cells with blood vessels developed (Fig. a). Less inflammatory cells infiltrated with slight of collagen deposition (Fig. b). Wound show well-arranged of new epithelium layer and compact collagen tissue less presence of inflammatory cells (Fig. c,d).

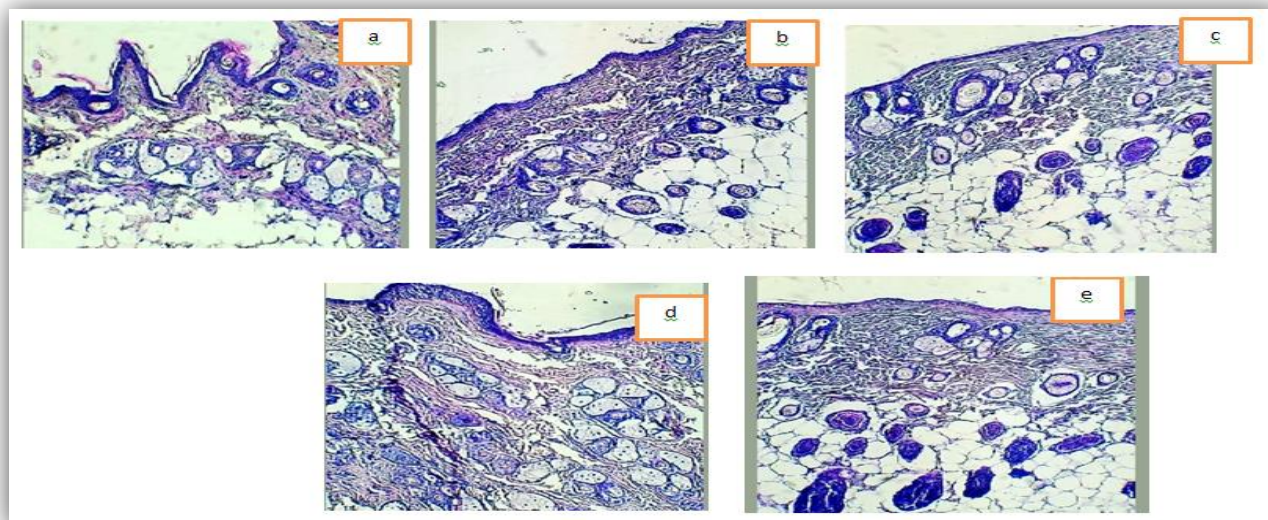


Figure (5): Histology of wound area stained with (H&E) after 15 days of treatment with different formulation of Curcumin extract show wound healing. A. curcumin extract ointment (5%), B. curcumin extract oily ointment (5%), C. curcumin extract oily ointment (2.5%), D. curcumin extract and clotrimazole oily ointment (2.5%), E. control group.

Several studies have been conducted to explore curcumin's ability of healing wounds by promoting epithelial regeneration, fibroblast proliferation, and vascular density, regulation of messenger or code to induce and accelerate the proliferation phase of wound healing. All these activities may remodel the effect of curcumin which appear as an active role in increasing granulomatous tissue formation, repair and collagen deposition. The effect of the extract formula on cellular hyperplasia and structure protein accumulation in granulation cells may explain why the extract formula showed complete epithelialization with keratinization as well as fibrous connective tissue multiplication and enhanced wound healing in the early stage [27].

The study revealed using of an oily composition has the potential to improve wound closure rates and collagen levels at the wound area [28]. Even though the wound healing activity of curcumin extract formula at the concentration (2.5%) showed significant results oily ointment alone and in conjunction with clotrimazole oily ointment demonstrated a competitive advantage in recovery activity over Curcumin extract in (5%) ointment alone [29]. Extract medicine that has a considerable influence on collagen depositing modification, as well as keratinocyte modulation and speed up the fundamental re-epithelialization mechanism. Finally, in Albino mice, the newly developed curcumin alone and in combination with clotrimazole improved wound healing and decreased the excise injured area.

Conclusion

In the current study, curcumin formulations potentially exhibited wound healing and inefficiently retarding and preventing bacterial infections. Also, it originated the combination of curcumin extracts with antibiotic (clotrimazole) that gave significant results using the ointment alone or mixing with clotrimazole in healing wounds to inhibit bacterial growth. Furthermore, the use of curcumin in various formulations successfully showed healing wounds with exceeds of ointment (2.5% w/v) compared to ointment (5% w/v). Thus, this study recommended applying the ointment (2.5% w/v) as an alternative treatment instead of other antibiotics.

References

1. D. Akbik, M. Ghadiri, W. Chrzanowski, and R. Rohanizadeh, "Curcumin as a wound healing agent" *Life Sciences*, vol. 116, no. 1, pp. 1–7, 2014.
2. D. K. Agrawal and P. K. Mishra, "Curcumin and its analogues: potential anticancer agents" *Medicinal Research Reviews*, Vol. 30, no. 5, pp. 818–860, 2010.
3. C. F. Lima, C. Pereira-Wilson, and S. I. S. Rattan, "Curcumin induces heme oxygenase-1 in normal human skin fibroblasts through redox signaling: relevance for anti-aging intervention," *Molecular Nutrition and Food Research*, Vol. 55, no. 3, pp. 430– 442, 2011.
4. G. Emiroglu, Z. Coskun, Y. Kalkan, O. Celebi Erdivanli, L. Tumkaya, S. Terzi, A. Özgür, M. Demirci, and E. Dursun. *The Effects of Curcumin on Wound Healing in a Rat Model of Nasal Mucosal Trauma .Evidence-Based Complementary and Alternative Medicine .Vol.1, pp.1-6 pages,2017.*
5. F. Groeber, M. Holeiter, M. Hampel, S. Hinderer, K. Schenke-Layland, Skin tissue engineering– in vivo and in vitro applications. *Adv Drug Deliv Rev. J. vol. 63, no.(4–5), pp. 352–366, 2011.*
6. Devi K, Santhi M, Umadevi U. Phytochemical analysis of selected wound healing medicinal plants. *Int J Pharm Sci Res.*, vol.8, no.(2), pp.1- 852, 2017.
7. Bahramsoltani R, Farzaei M.H, Rahimi R. Medicinal plants and their natural components as future drugs for the treatment of burn wounds: an integrative review. *Arch Dermatol Res.*, vol.306, no.(7), pp.601–617, 2014.
8. Gamit R, Nariya M, Acharya R, Shukla VJ. Wound healing potential of some medicinal plants with their screening models: a review. *Pharma Sci Monit.*; vol.8, no.(1), pp.208– 227, 2017.
9. Hosein F.M, Abbasabadi Z, Reza S.M, Abdollahi M, Rahimi R. A comprehensive review of plants and their actives constituents with wound healing activity in traditional Iranian medicine. *Wounds J.*; 26(7):197–206, 2014.
10. [10] Surendran Saritha.A., Vinaya O.G. Formulation evaluation and optimization of Clotrimazole solid Dispersion Incorporated Gels. *J. Medical Pharmaceutical and Allied Sciences. Vol.04; pp.42-51, (2014)*
11. Mordorski B, Prow T. Nanomaterials for wound healing. *Curr Dermatol Rep.*; vol.5, no.(4), pp.278–286, 2016.
12. Li S, Zhang T, Xu W, et al. Sarcoma-targeting peptide-decorated polypeptide nanogel intracellularly delivers shikonin for upregulated osteosarcoma necroptosis and diminished pulmonary metastasis. *Theranostics. J.*; vol.8, no.(5), pp.1361–1375, 2018.
13. Parihar A, Parihar M.S, Milner S, Bhat S. Oxidative stress and anti-oxidative mobilization in burn injury. *Burns J*; vol.34, pp.6-17, 2008.
14. Saaq M, Ahmad S, Salman Zaib M. Burn wound infections and antibiotic susceptibility patterns at Pakistan Institute of Medical Sciences, Islamabad, Pakistan. *World J Plast Surg*; vol.4 no.(1), pp.1-4, 2015.
15. [15] F. D. Marquele, K. M. Stracieri, M. J. V. Fonseca, L. A. P. Freitas. Spray-dried propolis extract. I: Physicochemical and antioxidant properties. *Pharmazie J.*, vol.61, pp. 325–330, 2006 .
16. [16] Ramber S, Chandra R, Bose M, Luthra PM. Antibacterial activity of *Curcuma longa* rhizome extract on pathogenic bacteria. *Curr. Sci. ; vol.83, no.(6), pp. 737-740, 2002.*
17. SAS Institute. *SAS/STAT® 9.2 User's Guide*. SAS Institute: Cary, NC, pp.1-3, 2008.
18. Cicchetti, E. and A. Chaintreau,. Comparison of extraction techniques and modeling of accelerated solvent extraction for the authentication of natural vanilla flavors. *J. Sep. Sci.*, vol.32, pp. 1957-1964, 2009.
19. Schrand AM, Rahman MF, Hussain SM, Schlager JJ, Smith DA, Syed AF. Metal-based nanoparticles and their toxicity assessment. *Wiley Interdiscip Rev Nanomed Nanobiotechnol.*; vol.2, no.(5), pp.544–568, 2010.
20. Haseeb MT, Hussain MA, Abbas K, et al. Linseed hydrogel-mediated green synthesis of

- silver nanoparticles for antimicrobial and wound dressing applications. *Int J Nanomedicine*.;vol.12,pp. 2845–2855,2017.
21. Choudhary MK, Kataria J, Cameotra SS, Singh J. A facile biomimetic preparation of highly stabilized silver nanoparticles derived from seed extract of *Vignaradiata* and evaluation of their antibacterial activity. *ApplNanosci*.;vol.6,no.(1),pp.105–111, 2016.
 22. Thomas R, Soumya KR, Mathew J, Radhakrishnan EK. Electrospun polycaprolactone membrane incorporated with biosynthesized silver nanoparticles as effective wound dressing material. *ApplBiochem Biotechnol*.;vol.176, no.(8),pp.2213–2224, 2015.
 23. Krychowiak M, Grinholc M, Banasiuk R, et al. Combination of silver nanoparticles and *Droserabinata* extract as a possible alternative for antibiotic treatment of burn wound infections caused by resistant *Staphylococcus aureus*. *PLoS One*.;vol.9,no.(12),pp.115727,2014
 24. Al-Shmgani HSA, Mohammed WH, Sulaiman GM, Saadoon AH. Biosynthesis of silver nanoparticles from *Catharanthusroseus* leaf extract and assessing their antioxidant, antimicrobial, and wound-healing activities. *Artif Cells Nanomed Biotechnol*.;vol.45,no.(6),pp.1234–1240, 2017.
 25. Shankar S, Jaiswal L, Aparna RSL, Prasad RGV, Kumar GP, Manohara CM. Wound healing potential of green synthesized silver nanoparticles prepared from *Lansiumdomesticum* fruit peel extract. *Mater Express*. Vol.5,no. (2),pp.159–164,2015.
 26. Wen L, Zeng P, Zhang L, Huang W, Wang H, Chen G. Symbiosis theory-directed green synthesis of silver nanoparticles and their application in infected wound healing. *Int J Nanomedicine*. Vol.11,pp.1-2757,2016.
 27. Kumarasamyraja D, Swamivelmanickam M. Evaluation of wound healing activity of biosynthesized silver nanoparticles from aqueous extract of *Cassia Auriculata* L. *Int J Phytopharm*.;vol.5,pp.201–209,2014.
 28. GhoshAuddy R, Abdullah MF, Das S, Roy P, Datta S, Mukherjee A. New guar biopolymer silver nanocomposites for wound healing applications. *Biomed Res Int*. vol.1, no.(5),pp.1–8,2013.
 29. Sivaranjani V, Philominathan P. Synthesize of titanium dioxide nanoparticles using *Moringaoleifera* leaves and evaluation of wound healing activity. *Wound Medicine*.;vol.12,pp.1–5, 2016.